

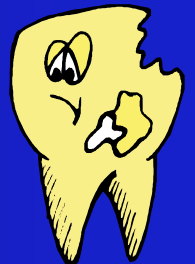
Differential Diagnosis and Treatment of Dental Emergencies in the HIV-positive Patient



Janet E. Leigh, BDS, DMD

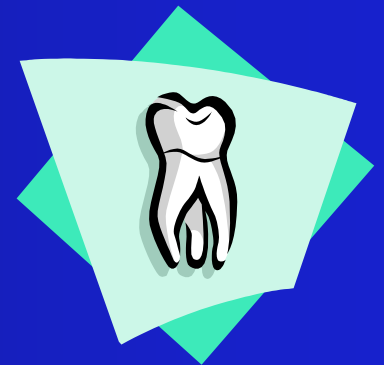Introduction

- Dental disease is evident in all patient populations regardless of medical condition
- Dental disease most commonly occurs because of dental neglect, however, HIV has certain unique oral health issues
- Dental care consistently ranks in the top five unmet needs in Statewide Statement of HIV/AIDS Needs Surveys



Goal

- Enable primary health care provider to identify emergency versus routine dental conditions
- Identify when treatment can and should be initiated in the medical office
- Recognize the appropriate time requirements for dental referrals

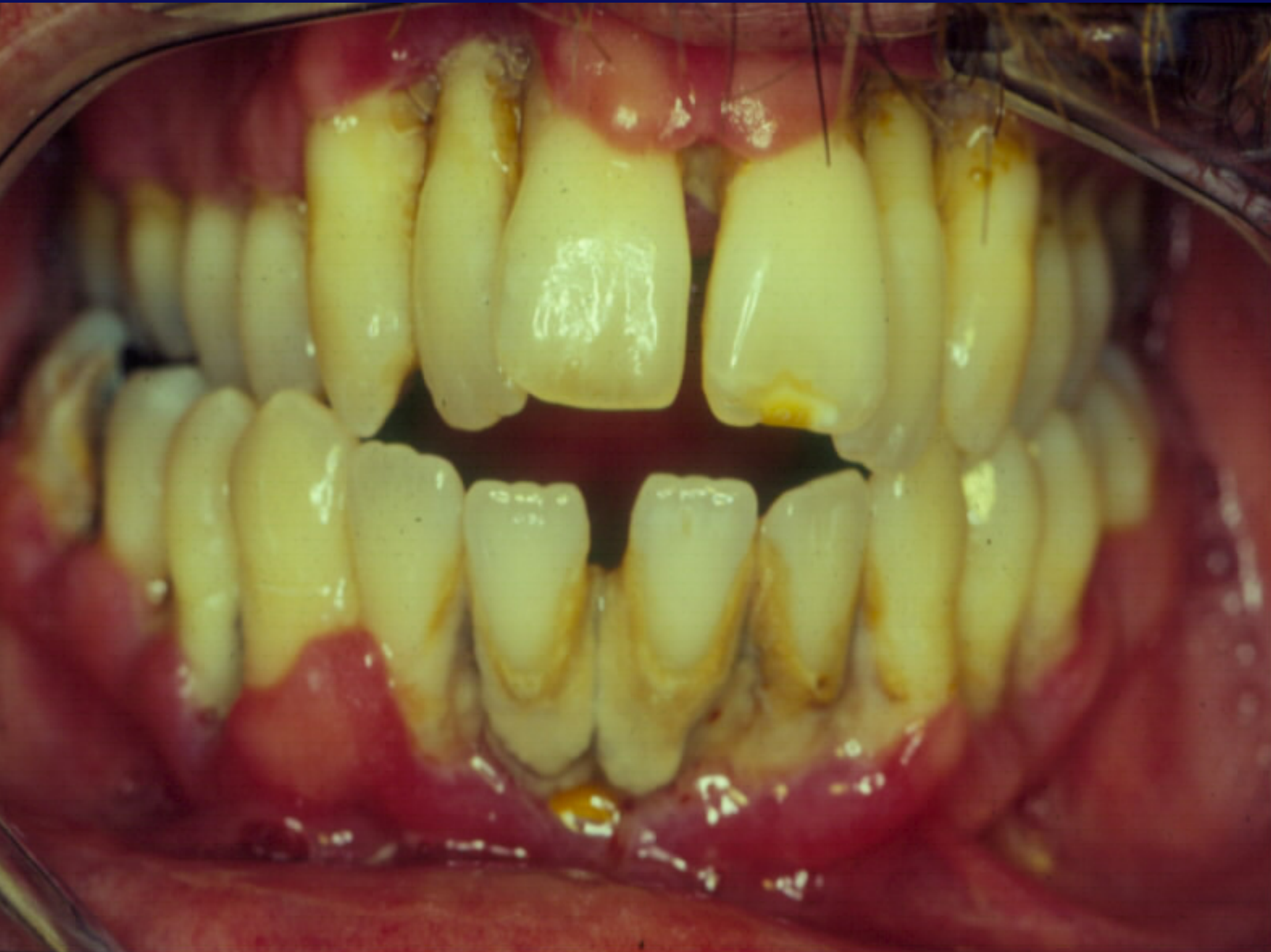

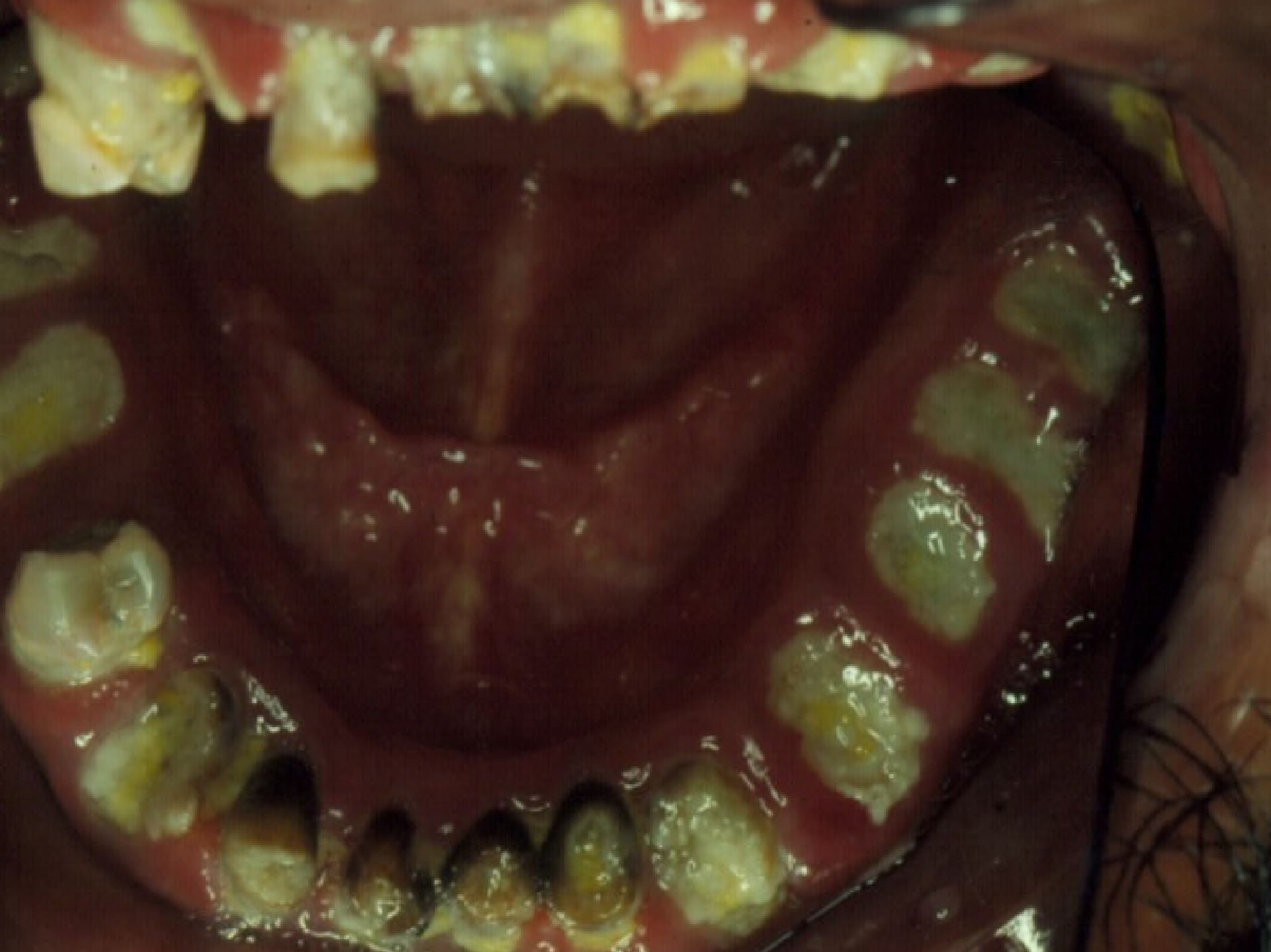Course overview

- Differential diagnosis of oral/dental pain
- Treatment options in the medical office
 - Appropriate use of analgesics
 - Appropriate use of antibiotics
- Dental emergencies requiring rapid referral to an emergency room
- Dental emergencies requiring referral to a dentist, and the appropriate time frame for that referral

Diagnosis of dental emergencies in the medical office

- What level of emergency?





What is a true dental emergency?

- The presence of pain does not necessarily constitute a dental emergency

An acute emergency requires the presence of:

- Swelling
- Fever
- Pus
- Bleeding

What is a true dental emergency?

- The presence of pain does not necessarily constitute a dental emergency

An acute emergency requires the presence of:

- **Swelling**
- Fever
- Pus
- Bleeding

Swelling - Questions to ask

Is it

- Diffuse
 - Does it spread up to the eye/cheek
 - Does it spread into the neck
- Discreet
- Fluctuant

Swelling - Questions to ask

- Is this the first time it has happened
- When did it start

Does it

- Feel like it's interfering with swallowing or breathing
- Change the way the patient speaks

Swelling

The Swollen Face

- Differentiate between Cellulitis and Abscess
- Evaluate airway and swallowing
- Can be difficult to evaluate intra-orally if trismus is present

Trismus

- Suggests an infection in the posterior region of the mouth
- Infection can cause a reactive myospasm, particularly of the masseter muscle
- Do not “force” the mouth open to evaluate the area
- The trismus will resolve once the infection is resolved

Ludwig's Angina: A True Medical/Dental Emergency

- Cellulitis involving bilateral sublingual, submandibular and submental spaces
 - Tongue is elevated to palate
- Rapid spread of the infection into the lateral- and retro-pharyngeal spaces can cause airway obstruction

When to Admit an HIV-positive Patient with an Odontogenic Infection


- Deep fascial space infection which threatens the airway
- Patient is dehydrated and requires IV fluids
- Patient requires general anaesthesia for surgical procedures

What is a true dental emergency?

- The presence of pain does not necessarily constitute a dental emergency

An acute emergency requires the presence of:

- Swelling
- **Fever**
- Pus
- Bleeding



Fever

- Painful submandibular/cervical lymphadenopathy would be expected
- A tooth causing a fever would be tender to touch, percussion and palpation

What is a true dental emergency?

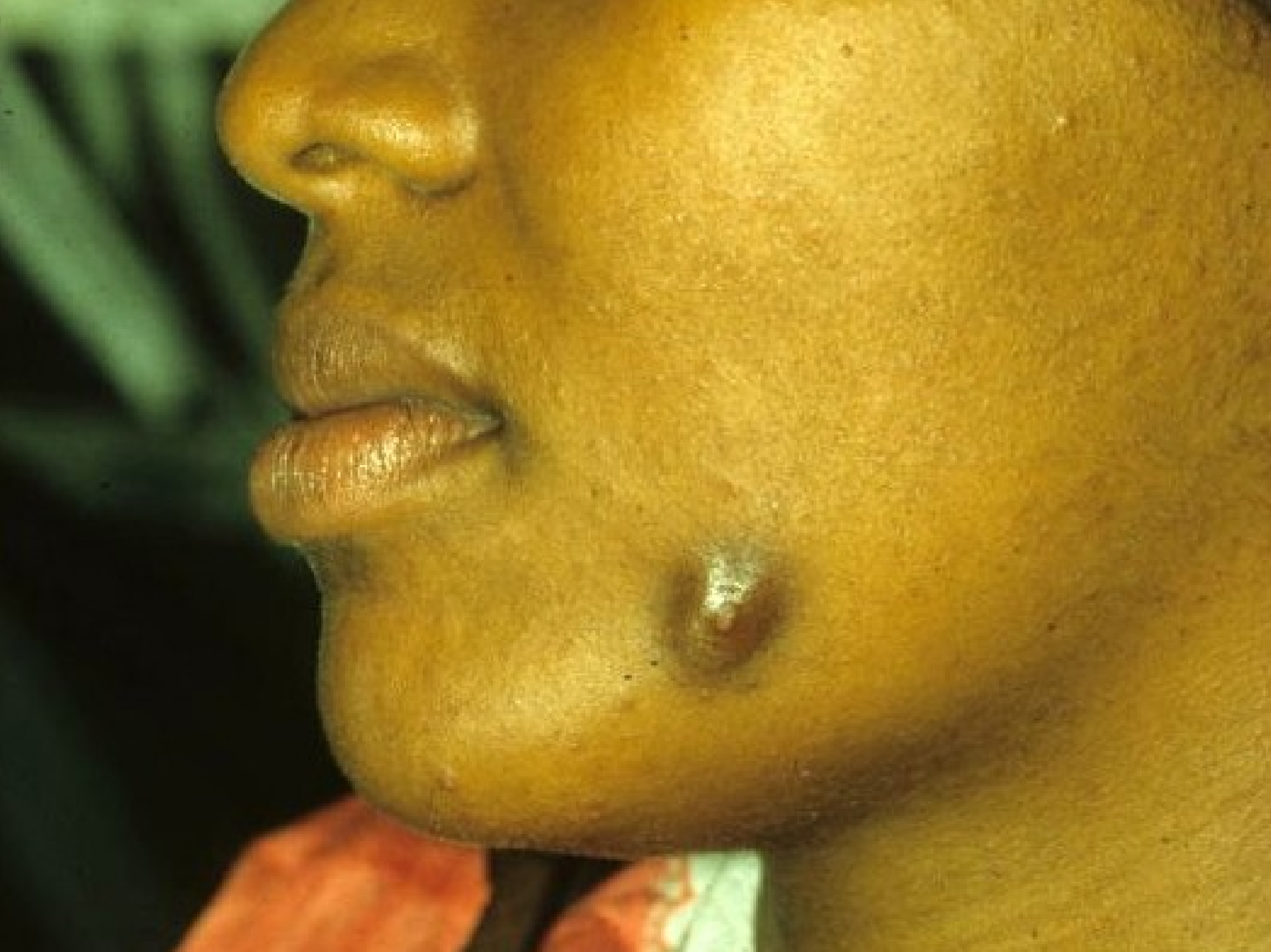- The presence of pain does not necessarily constitute a dental emergency

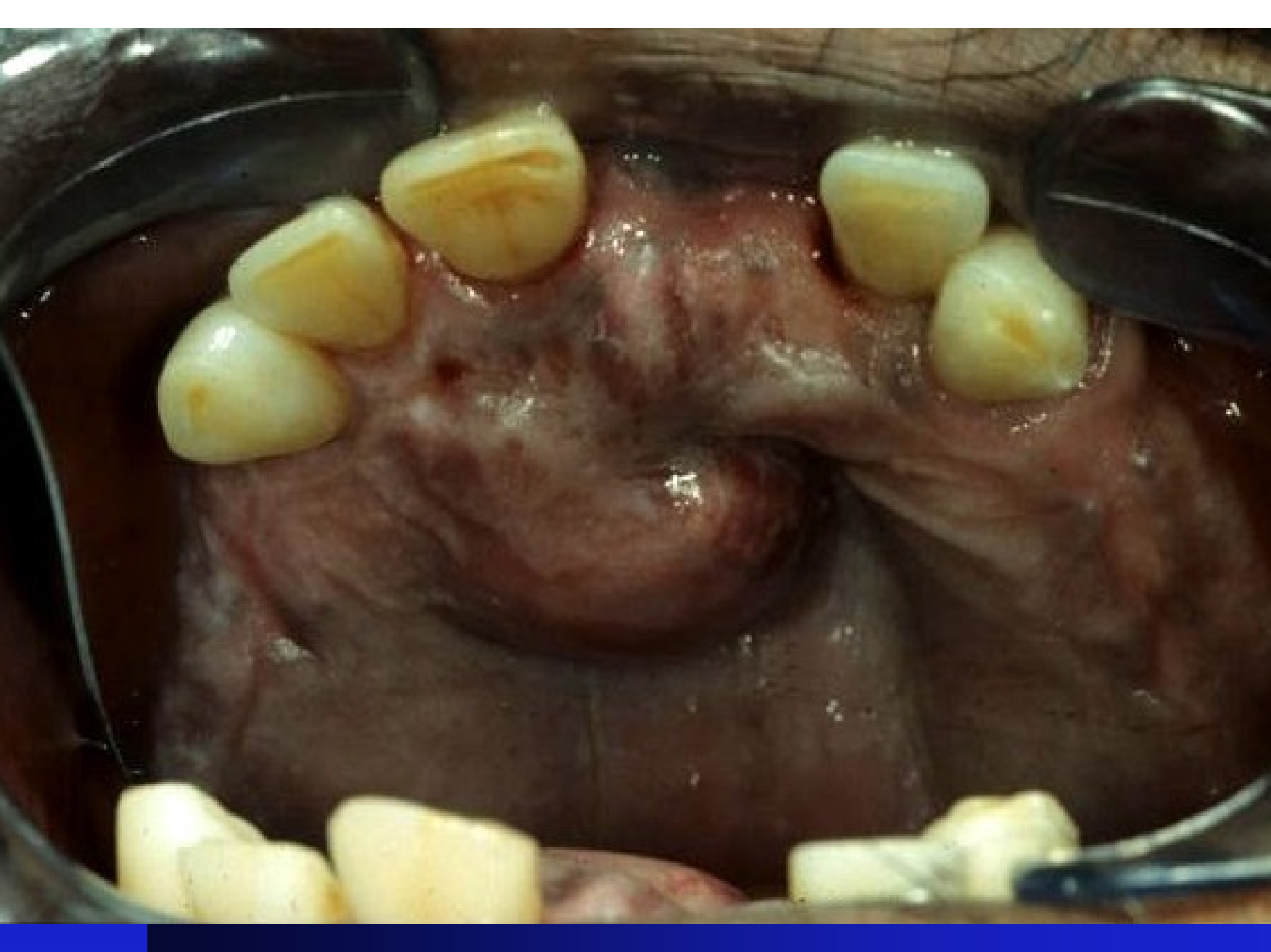An acute emergency requires the presence of:

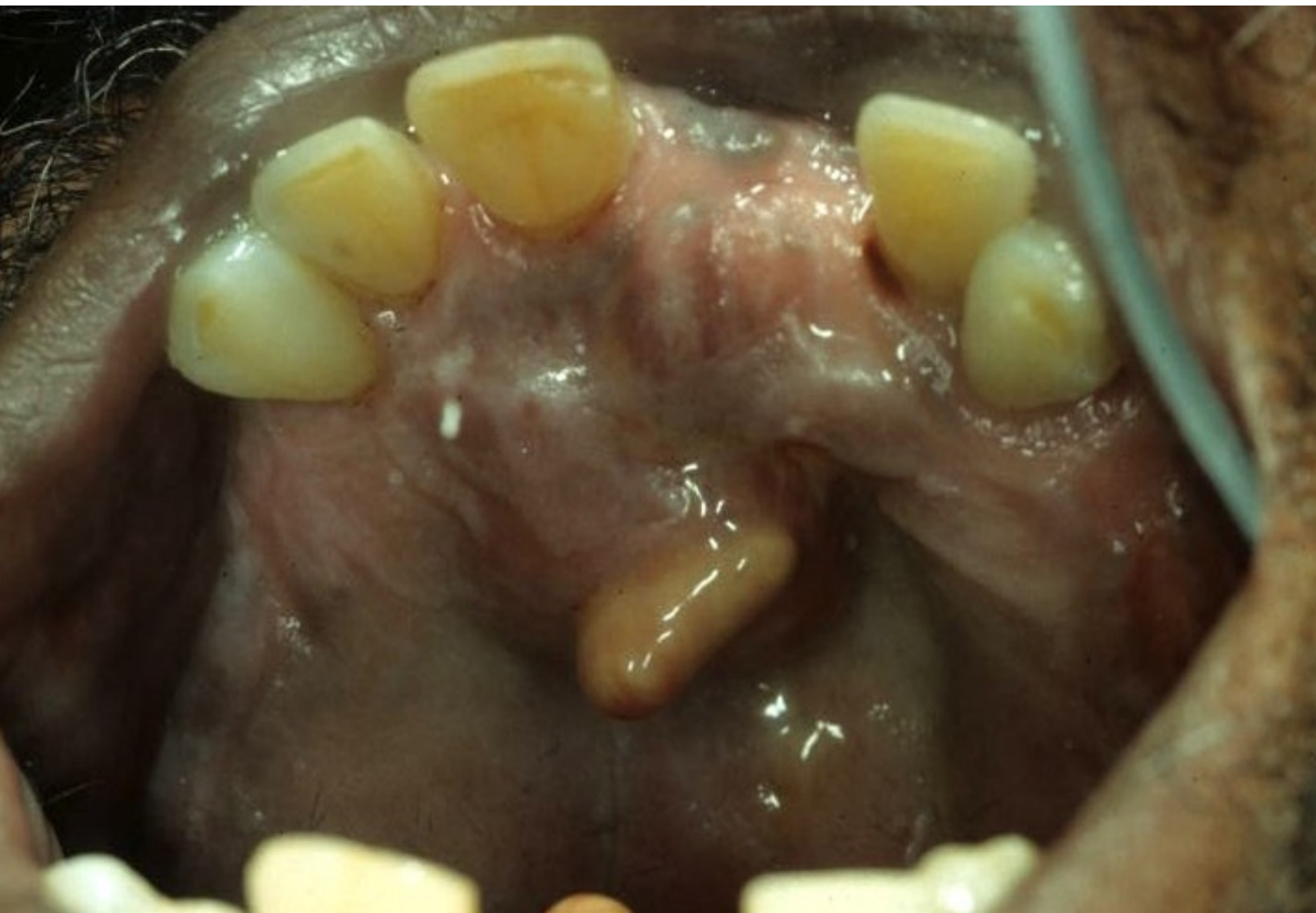- Swelling
- Fever
- **Pus**
- Bleeding

Pus

- Drainage is always the best
- Drainage should be encouraged INTRA-ORALLY!
- Extra-oral drainage leads to significant scarring
 - Discourage the application of hot compresses to the skin overlaying the swelling







Intra-oral Drainage

- Rinse with hot salt water mouth rinses every two hours until drainage occurs

Intra-oral Drainage

- Rinse with hot salt water mouth rinses every two hours until drainage occurs
 - How hot? – almost as hot as you drink your tea



Intra-oral Drainage

- Rinse with hot salt water mouth rinses every two hours until drainage occurs
 - How hot? – almost as hot as you drink your tea
 - How long? – Swish over swollen area until the water starts to cool, spit it out and take another mouthful. Do this for at least five minutes every two hours

Intra-oral Drainage

- Rinse with hot salt water mouth rinses every two hours until drainage occurs
 - How hot? – almost as hot as you drink your tea
 - How long? – Swish over swollen area until the water starts to cool, spit it out and take another mouthful. Do this for at least five minutes every two hours
- Then continue Q.I.D. until dental treatment can be obtained

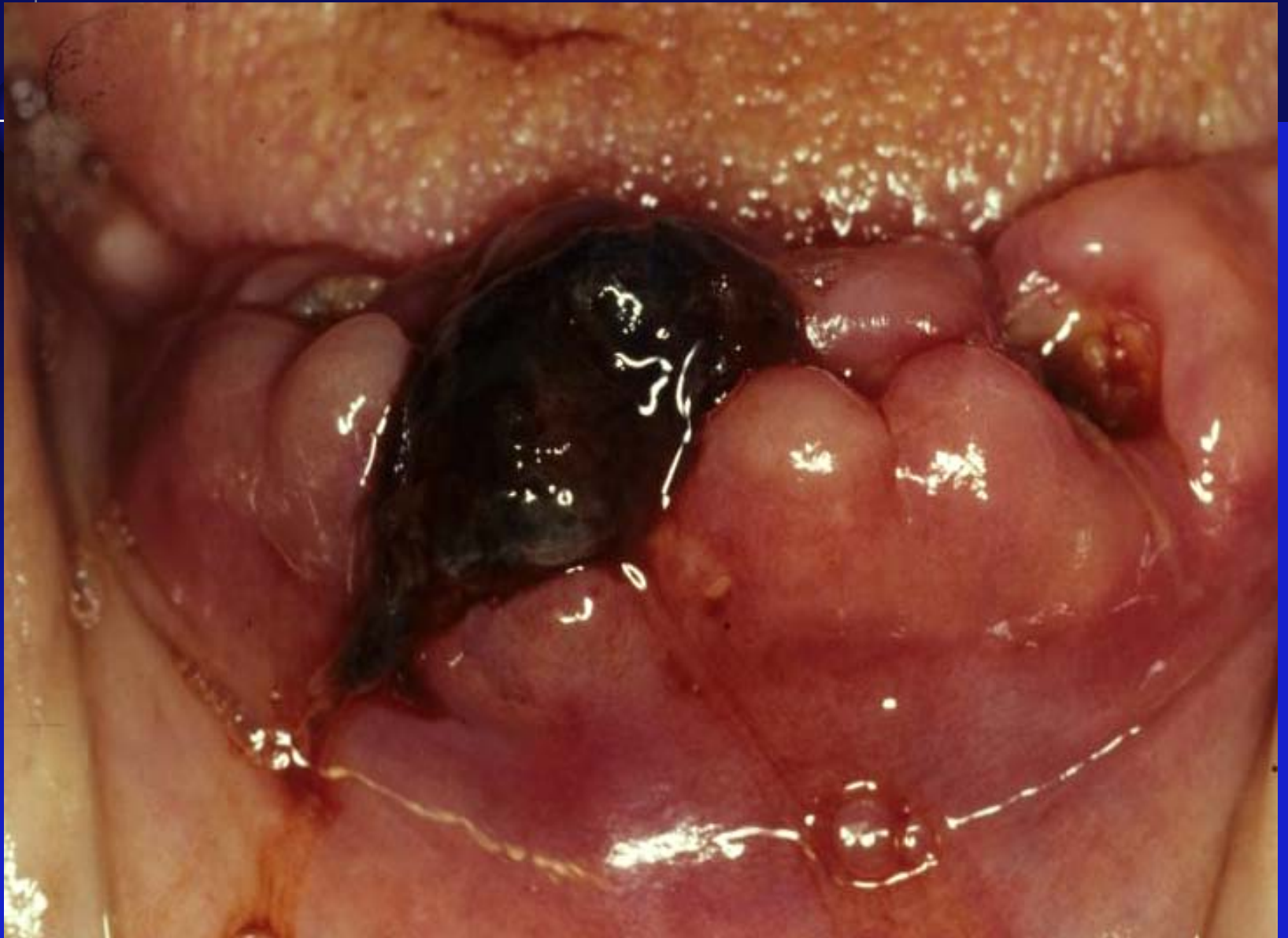What is a true dental emergency?

- The presence of pain does not necessarily constitute a dental emergency

An acute emergency requires the presence of:

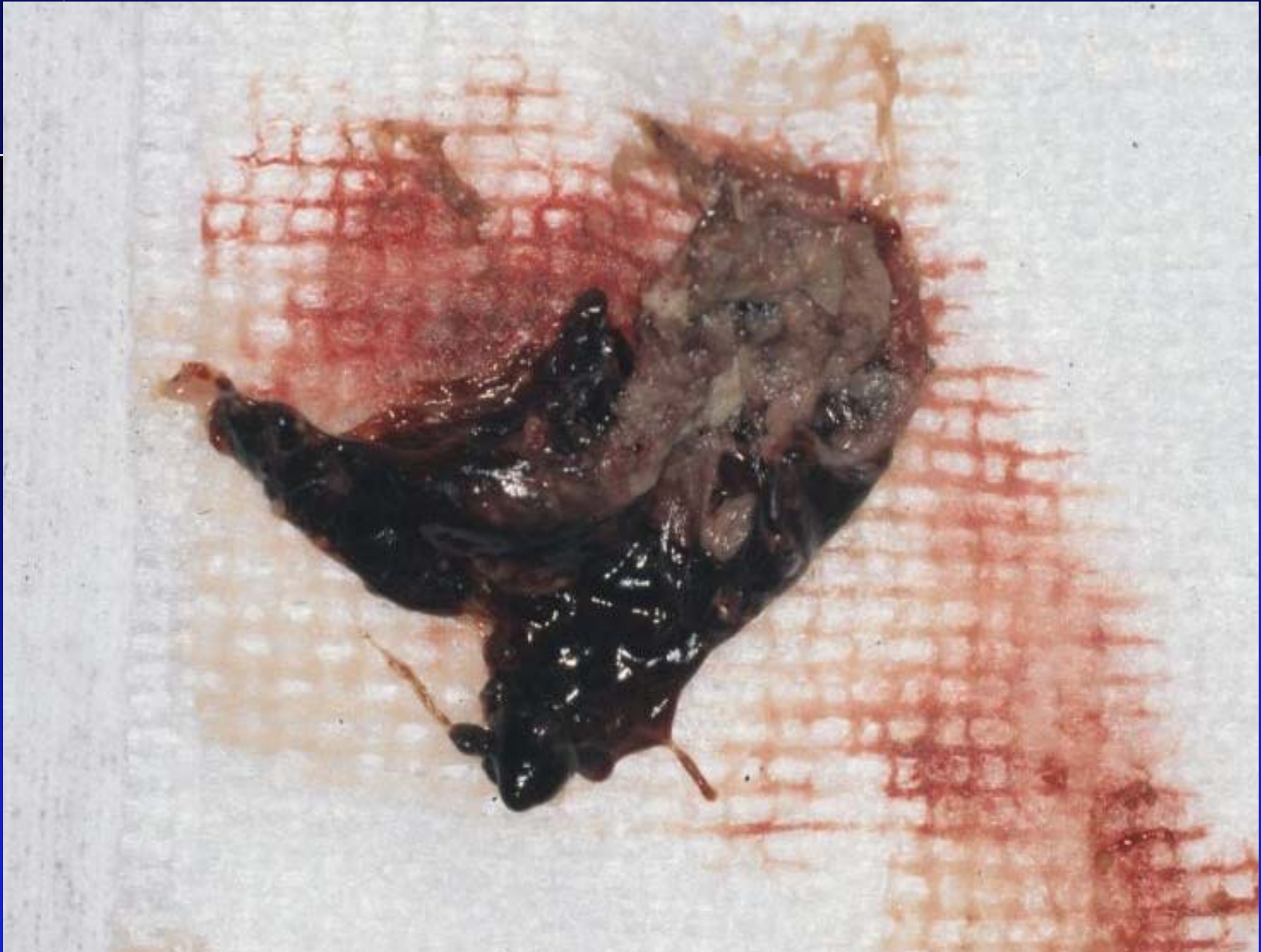- Swelling
- Fever
- Pus
- **Bleeding**



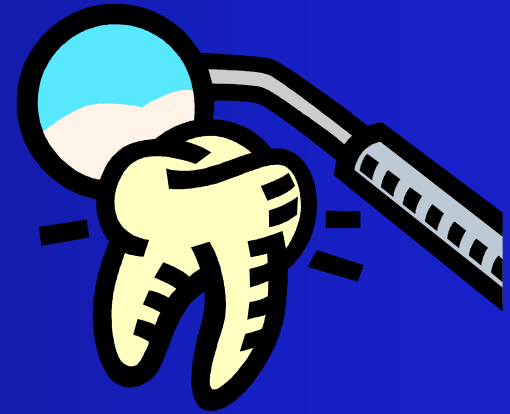

Bleeding

- Occurs most commonly in patients who have recently had a tooth extracted
- Associated with
 - Liver disease
 - Platelet dysfunction
 - Aspirin/NSAID use



Treatment options in the medical office



Treatment options in the medical office

- Can I aid in the diagnosis of this problem
- What should I do for the patient while we are waiting for a dental appointment
- Can this problem be dealt with without a dental referral

Origins of Dental Emergencies

Hard Tissue

- Teeth
- Bone

Soft Tissue

- Periodontium
- Mucosa



Origins of Dental Pain

- The majority of dental pain originates in the teeth or periodontium and is relatively easy to treat with analgesics and antibiotics

Treatment starts in the medical clinic but dental referral required

Origins of Dental Pain

- Mucosal pain is often more difficult to treat, if due to ulceration
 - Diagnosis and treatment of ulcerative periodontal conditions in the medical setting is difficult – Urgent referral required
 - Diagnosis and treatment of ulcers - possible in the medical setting

Dental Pain

- The majority of dental pain problems require direct treatment of a dental structure
- Dental problems do NOT “cure themselves”
- Treating the pain without treating the underlying cause only prolongs the problem



Dental Pain - Questions to ask

What does the pain feel like

- Quality of pain
 - Describe the pain (Sharp, Stabbing, Dull, Throbbing)
- This gives a clue to the origin

Where does the pain occur

- Pain can be referred to other teeth or to the ear

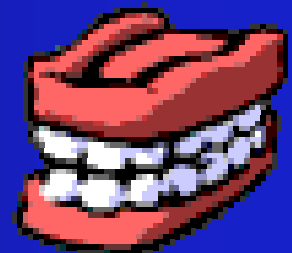What are the clues?

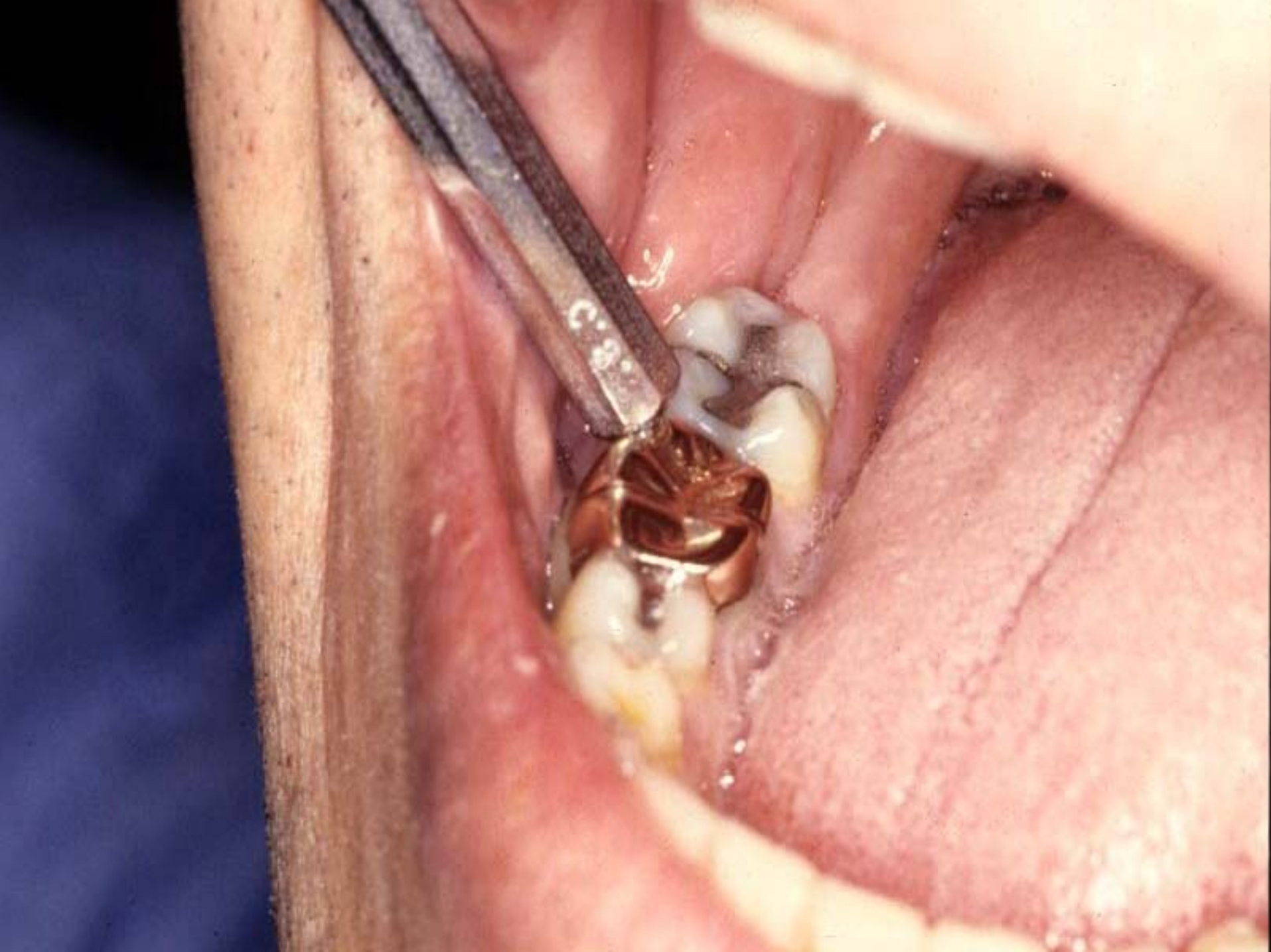- The quality of pain can suggest a pulpal or periodontal or periapical problem and help direct you to the appropriate action i.e Refer or treat in your office
- **REMEMBER!!** All dental pain problems will eventually require the dentist's intervention!!

Dental Pain - Questions to ask

What brings the pain on

- What initiates the pain
 - Eating, drinking (hot,cold,chewing)
 - Lying down in bed
 - Movement





Dental Pain - Questions to ask


How long does it last

- A sharp pain that lasts for seconds when drinking a cold drink would suggest a pulpitis
- Does the pain last after you stop biting the tooth
- A dull throbbing pain that lasts a while suggests an abscess

Differential Diagnosis of Dental Pain - Questions to ask

What helps alleviate the pain

- Does Tylenol or Advil take the pain away?
- Does rinsing with warm water help?



Pain control

- Pain control is necessary in order for the patient to eat and function normally
- Few oral pains require the use of opioid analgesia
- Rapid analgesia is available in your office!
- How often should you refill analgesia prescriptions?

Non-steroidal analgesics

- THE BEST! – Ketorolac IM (30mg or 60mg)
- Oral
 - Ibuprofen – 600mg QID
 - Ketorolac – 10mg QID (not to exceed 5 days)
 - Whichever NSAID you are comfortable using

Opioid analgesics

- One of the few times that opioid analgesics are useful is in the presence of deep bone pain
 - Necrotizing ulcerative periodontitis
- Use of an opioid combined with an anti-inflammatory is recommended
 - Lortab (Hydrocodone 5mg and Aspirin 500mg)
1-2 tablets every 4-6 hours

Mucosal analgesics

Liquid

- Benadryl elixir 12.5mg/5ml
- Viscous Lidocaine
 - **NEVER** swish with this! Apply to ulcer with a Q-tip
- Tetracycline liquid 125mg/5ml
- Decadron elixir 0.5mg/ml

Mucosal analgesics

Paste/ointment

- Kenalog in orabase[®]
 - Apply to lesion TID
- Lidex (0.05% Fluocinonide) mixed 50:50 with orabase[®]
 - Apply to lesion QID

What about prescribing antibiotics?



Use of Antibiotics

- Depends on whether this is a local or a systemic problem
- Local
 - Go with local measures – drainage
- Systemic
 - Encourage drainage
 - Combine it up with antibiotic use

Antibiotics in Dentistry

- Penicillin VK (500mg)

two tablets stat then one tablet QID

- Hits gram positive bacteria, the bacteria most commonly associated with dental abscesses
- Inexpensive
- If not on your formulary use Amoxicillin

Broad Coverage Antibiotics in Dentistry

- Penicillin VK (500mg)
plus
- Metronidazole (250mg) QID
 - Hits both gram positive AND gram negative bacteria

Broad Coverage Antibiotics in Dentistry

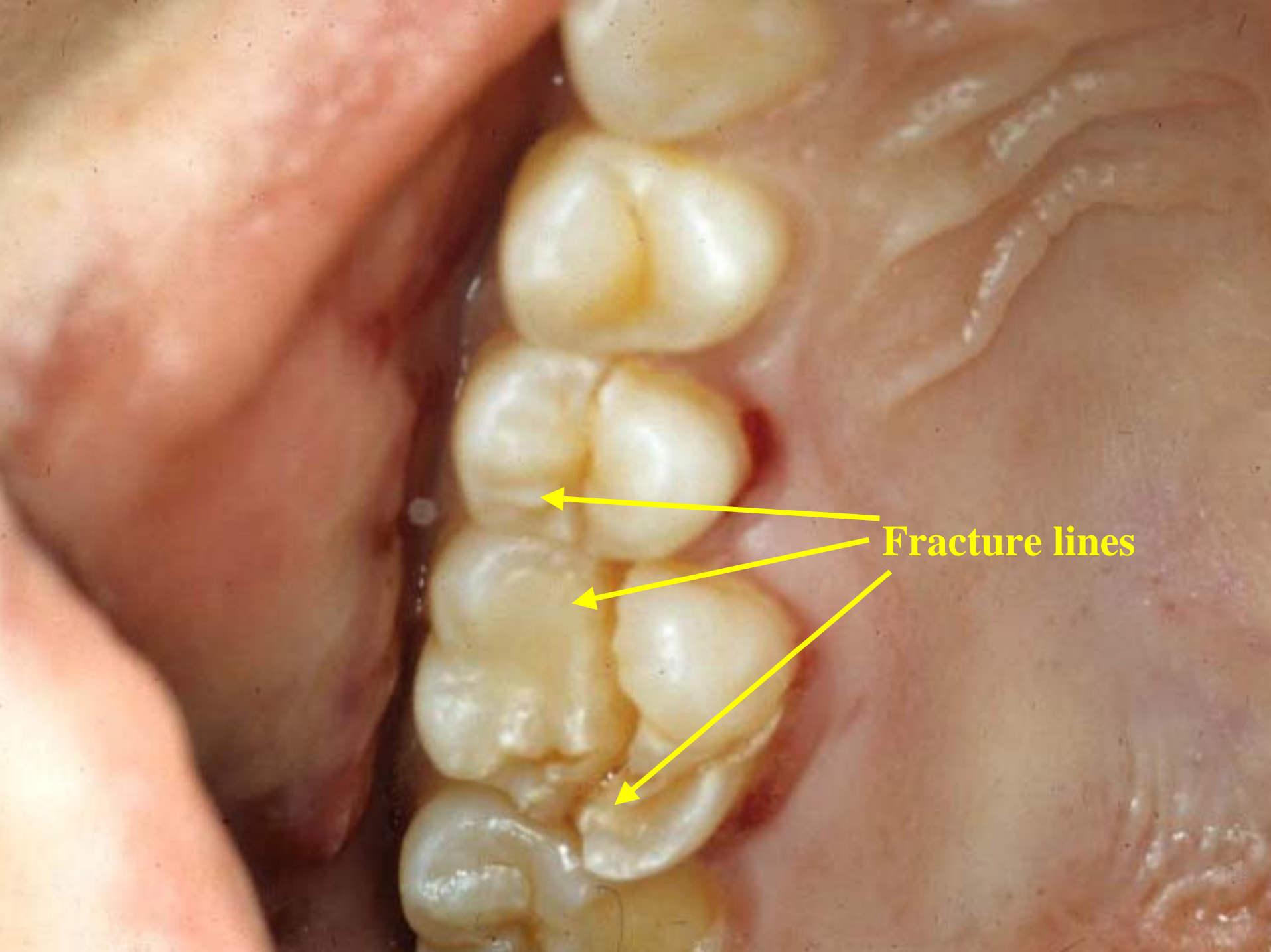
- Clindamycin (300mg)
 - two tablets stat then one tablet TID
 - Hits both gram positive AND gram negative bacteria
 - More common on clinic formularies

A few examples!




Broken Tooth

- Sharp pain on eating, biting or drinking a cold drink, usually brief but may linger
- This is a pulpal pain
- There's not much you can do for this patient!
Recommend immediate referral to a dentist
- Use of “temporary filling material” available in drug stores
- This is an inflammatory pain – treat with aspirin or NSAIDs



Fracture lines

Broken Tooth



Medical Office

- Recommend temporary filling
- Prescribe NSAIDs


Dental Referral

- Immediate/urgent

Sinusitis

- A dull aching pain in the back top teeth that seems to be constant. It gets worse when the patient grinds their teeth or goes jogging or walking up and down stairs
- This isn't a true dental pain, it just presents like one!
- Antibiotic use is required

Sinusitis



Medical Office

- Antibiotics

Dental Referral

- Wait and see the response to antibiotics

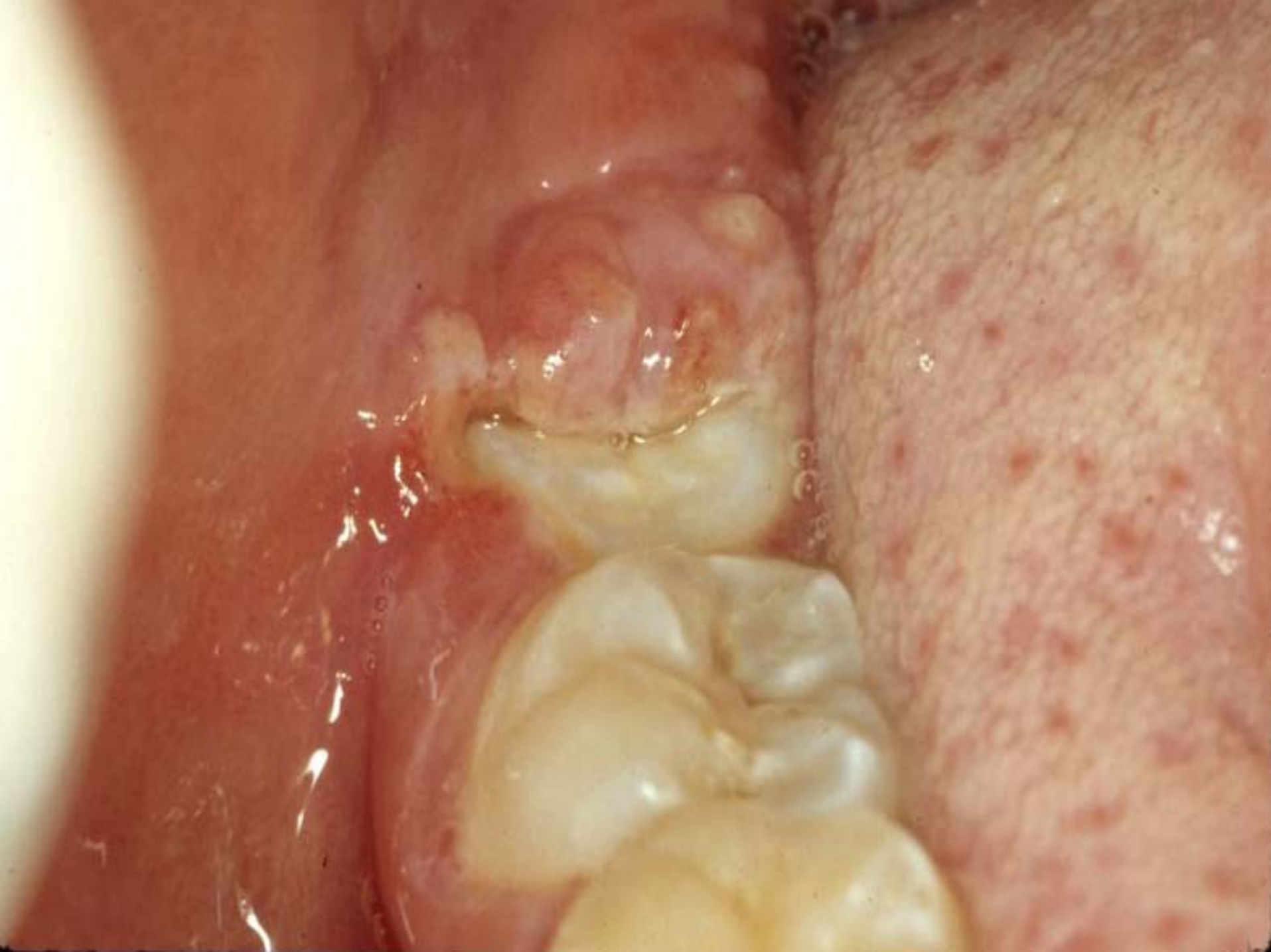Impacted wisdom tooth

- Deep sharp pain when the patient bites down that then becomes a dull ache with pain up in the ear
- This patient needs to see a dentist to have the tooth extracted
- In your office
 - Hot salt water rinses should be recommended
 - NSAIDS will help
 - May need antibiotics

Wisdom Teeth/Pericoronitis

More common in the mandible

- Can present with Pain, Swelling and Trismus
- Inflamed soft tissue covering a partially erupted tooth
- Suppuration between soft tissue and the tooth



Wisdom Teeth

More common in the mandible

- Can present with Pain, Swelling and Trismus
- **Pain is often due to the upper wisdom tooth biting on the inflamed tissue overlying the bottom tooth**

Wisdom Teeth

More common in the mandible


- Can present with Pain, Swelling and Trismus
- Pain is often due to the upper wisdom tooth biting on the inflamed tissue overlying the bottom tooth
- **Swelling indicates local infection**

Wisdom Teeth

More common in the mandible

- Can present with Pain, Swelling and Trismus
- Pain is often due to the upper wisdom tooth biting on the inflamed tissue overlying the bottom tooth
- Swelling indicates local infection
- **Trismus occurs secondary to spasm of the masseter muscle**

Impacted Wisdom Tooth



Medical Office

- Hot salt water mouth washes
- Antibiotics (if swollen or trismus present)
- NSAIDS

Dental Referral

- Within two weeks


Mucosal Pain

- Severe sharp pain that never seems to go away
- In the HIV-positive patient this is most likely secondary to ulcerations
- Try to keep the pain medications located on the ulcer itself to prevent “numbing” of the whole mouth which diminishes appetite and nutritional intake

Oral Ulcers

- Diagnosis
 - Cytology to rule out viral aetiology
- Pain control
 - Rinses
 - Pastes
 - Viscous lidocaine

Oral Ulcers



Medical Office

- Diagnosis
 - Cytology
- Analgesia


Dental Referral

- Urgent (if cytology results are inconclusive)
 - Biopsy

Herpetic Ulcers

- Severe sharp pain
- Most commonly occur on keratinized surfaces
- Healing starts within 48 hours with Acyclovir or Valcyclovir

Herpetic Ulcer



Medical Office

- Cytology
- Treat
 - Acyclovir/Valcycloir


Dental Referral

- Biopsy if cytology is inconclusive

Necrotizing Ulcerative Periodontitis

- This is a deep seated intense/severe pain
- Initial treatment
 - Gentle debridement
 - Betadine rinse
 - Antibiotics
 - Narcotic analgesics

Necrotizing Ulcerative Periodontitis



Medical Office

- Diagnose
- Treat (only if dental not available)
 - Debride
 - Betadine rinse
 - Analgesia

Dental Referral

- URGENT!

TREATMENT



- **Debridement**
- **Irrigation with povidone-iodine solution**
- **Chlorhexidine(0.12%) rinses**
- **Antibiotics (Metronidazole/ Clindamycin)**
- **Scaling and prophy**

Dental emergencies requiring referral to an emergency room

- Infections causing compromised airway
- Patient is dehydrated secondary to poor fluid intake
- Rapidly increasing/spreading swelling of the head or neck

Dental emergencies requiring referral to a dentist

- All dental emergencies should be evaluated by a dentist
- The speed of that referral depends on
 - Access to an appointment
 - The delivery of appropriate care in the medical office



Summary

- Differential diagnosis of oral/dental pain
- Treatment options in the medical office
 - Appropriate use of analgesics
 - Appropriate use of antibiotics
- Dental emergencies requiring rapid referral to an emergency room
- Dental emergencies requiring referral to a dentist, and the appropriate time frame for that referral